

Short Scar Face-Lift with the Use of Fibrin Sealant

Samieh S. Rizk, MD^{a,b,*}

^aDepartment of Facial Plastic Surgery–Head and Neck Surgery,
Manhattan Eye, Ear, and Throat Hospital and Lenox Hill Hospital, New York, NY, USA

^bManhattan Facial Plastic Surgery, New York, NY, USA

Fibrin sealants have been used in surgical procedures for decades. First applied in intracranial surgery in 1915 [1], they have also been used in otolaryngologic surgery for sealing cerebrospinal fluid leaks; thoracic surgery for primary repair of thoracic duct leaks and esophageal anastomoses [2]; general surgery for colostomy closure and splenic repair; orthopedic surgery for tendon repairs [3]; and plastic surgery for skin grafts [4], rhytidectomy [5], blepharoplasty [6], and endoscopic forehead lift [7]. The application of tissue adhesives is becoming more popular in aesthetic and reconstructive surgery for many reasons. The success of fibrin glue in potentially limiting hematoma and seroma formation, and ecchymosis and edema, while reducing the need for drains in face-lift surgery, has brought this agent to the attention of aesthetic surgeons. Its safety profile over the years with better selection and purification processes has virtually eliminated the chance of bacterial or viral contamination [8,9]. The hemostatic and sealant properties of the Tisseel fibrin sealant remain in the first 2 weeks postoperatively, resulting in a more rapid recovery.

This article focuses on the short scar face-lift and the applicability of Tisseel fibrin sealant, or “tissue glue,” in expediting the healing process in a series of consecutive patients undergoing face-lift surgery by

two surgeons (SR and AM). The authors began using fibrin sealants over a decade ago, but until recently they were not standard in their practice. With regard to the use of the short scar incision, it has always been their practice in younger patients to perform an upper face-lift where the incision begins on the temporal hairline, with or without a sideburn cut, and ends in the postlobule sulcus. It is only more recently, however, that they have applied the short transauricular rhytidectomy, without any hair-bearing incisions, in all patients regardless of degree of deformity, including the excessive neck deformities, age, gender, or prior history. Consequently, this form of surgery is known as 5-STAR (5–short transauricular rhytidectomy), but also as an upper face-lift, short scar face-lift, or minilift.

Although the debate continues to rage as to the optimal face-lift procedure, many agree that some characteristics of an ideal procedure would produce the shortest scars with the least morbidity and the best results [10]. Patients’ desire for less invasive procedures with an expedient recovery has served as an ongoing impetus for innovations in aesthetic surgery. The primary motivation for incorporating the tissue sealant into the short scar face-lift technique was to improve the coaptation of the dissected surfaces, enhance flap redraping, and diminish postoperative ecchymosis and edema. The addition of the fibrin sealant to face-lift surgery in the authors’ practice has further eliminated the routine use of drains. Fibrin sealants have reduced bruising, edema, pain, hematoma, and seroma formation, enabling a more rapid recovery. Drains often have mechanical problems (ie,

* Corresponding author. Manhattan Facial Plastic Surgery, 885 Park Avenue, New York, NY 10021.

E-mail address: drsamrizk@aol.com (S.S. Rizk).

leaks), may obstruct, rendering them ineffective, or may serve as a source of infection both as a foreign body and an entry point for bacterial contamination of the wound.

The evolution of the face-lift incision into the short scar and the adjunctive use of the Tisseel fibrin sealant have both resulted in faster recovery. Perhaps the most alluring advantage for the patient is the freedom of women to style and wear their hair according to their desires, avoiding any changes in hair density or position (including the mastoid hair-line stepoff and scar hypertrophy) and men to obtain short haircuts without concern that a hairline scar or distortion might be exposed. Tisseel's fibrin component allows it to seal the large raw surface created during rhytidectomy and to reduce oozing from smaller vessels, minimizing fluid collections, bruising, and edema.

Tisseel fibrin sealant basics

Tisseel fibrin sealant is a physiologic, nontoxic hemostatic agent that is partially derived from human plasma. The sealant components of human fibrinogen, human thrombin, and bovine aprotinin stimulate the natural process of healing by simulating clot formation at the final phase of coagulation [11,12]. Introduction of the Tissomat (Fig. 1) to facilitate mixing of the product and the atomizer dual-syringe spray (Fig. 2) to distribute the sealant evenly has also contributed to the acceptance of this product.

Tisseel fibrin sealant firmly adheres to connective tissue and has elastic properties that enable it to contour over pulsating areas. It is ideal for use over small areas of oozing but is not indicated for arterial

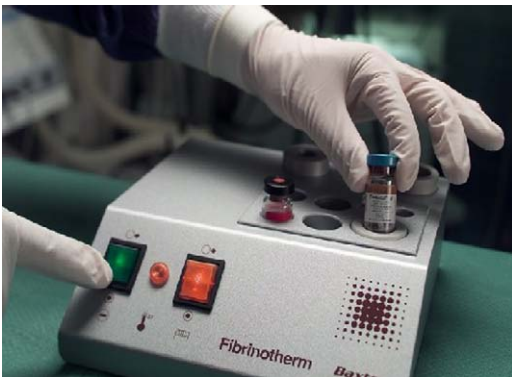

Fig. 1. Heating device for sealant.

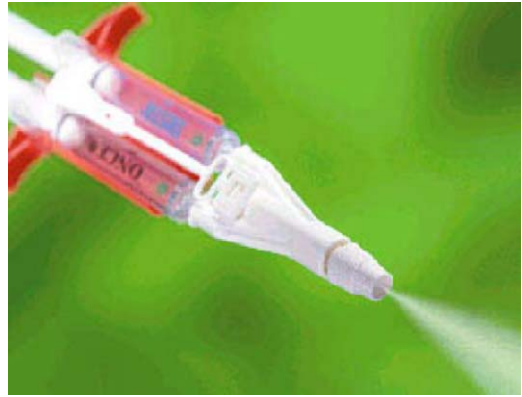

Fig. 2. Dual-projection delivery aerosolizing syringes.

bleeding. The tissue glue is indicated for sealing oozing on large raw surfaces [13]. It has not been associated with any caustic tissue damage when it is applied locally and is completely absorbed within 1 to 2 weeks [14]. Older fibrin sealants had higher sodium content that rendered the clots formed transparent, and more brittle. The low sodium content of newer formulations enables the thrombin to convert the fibrinogen to fibrin on the tissue surface. This creates a fibrin matrix with structured strands that are more effectively cross-linked by factor XIIIa and that form a stronger visible clot. Once the clot is formed, the bovine aprotinin component, the antifibrinolytic agent, reduces the rate of clot lysis by endogenous plasmin [15]. By sealing the raw surfaces of capillaries, postoperative bleeding, edema, pain, and the potential for hematoma formation are minimized.

Surgical technique

The face-lift technique is a result of a continuous evolution from the traditional open face-lift incision (Fig. 3), into the modified open technique (Fig. 4), and finally into the short scar face-lift (Fig. 5). All of the patients who have had this short scar face-lift also had concomitant suction-assisted lipoplasty, and most (75%) underwent a submentalplasty with a platysma-plasty. The short scar approach provides a shorter, more appealing, and well-hidden scar; essentially no hair abnormalities; potentially shorter operative time; and greater patient acceptance at the expense of a slightly narrower operative field with limited access to the orbicularis oculi muscle and temporalis muscle.

The short scar incision begins in the horizontal aspect of the sideburn; extends to the preauricular

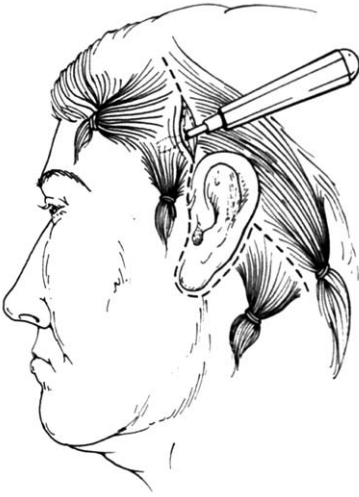

Fig. 3. Traditional open face-lift approach, which allows wider access (ie, the temporalis muscle).

region, either pre- or posttragal; curves around the ear lobe posteriorly up to the postauricular notch; and ends in the sulcus approximately 2 to 3 cm from the lobule. It spares incisions in the temporal and mastoid areas (see Fig. 5).

The short scar face-lift may require additional midline platysmal work, accounting for the higher rate of submentalplasty than is done with the traditional face-lift (76% versus 10.6%) [16]. The procedure begins with liposuction of the neck and

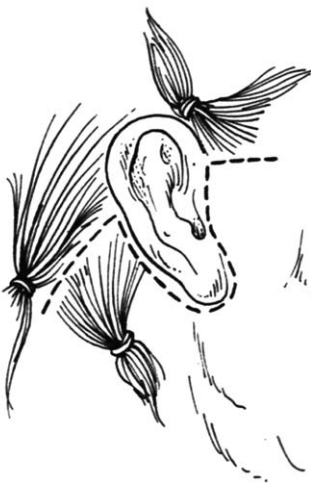


Fig. 4. Modified open face-lift approach. In the course of evolving to a short scar lift this was useful.

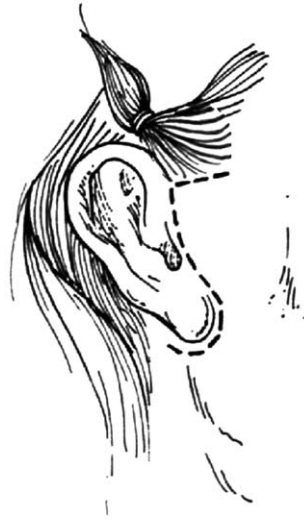

Fig. 5. 5-STAR incision. Note incision inside sideburn hairline, extending preauricularly (either pretragal or posttragal) and for a short distance postauricularly (short scar transauricular rhytidectomy).

jowels as indicated through a submental incision the midline platysma is isolated, and a wide strip wedge platysmaectomy is performed to shorten redundant platysma muscle and deepen the cervicomental angle. When fat excision is indicated, the exposed fat deep to the platysma muscle is excised under direct vision. The medial (anterior) borders of the platysma muscle are then identified, and a back cut is performed at the level of the hyoid. The medial borders are then sutured in the midline with a nonabsorbable suture. This medial vector pull on the platysma is important for defining the cervicomental angle and for the redraping of excess skin into the submental hollow that occurs with the short scar face-lift. It is not necessary or desirable to have excess lateral vector pull on the platysma.

The authors have found that “fatty necks” after being aggressively defatted often have a surprising degree of tissue elasticity and retraction and that less skin excision than expected is required accounting for the dramatic result that can be achieved in the short scar face-lift in “large” necks. In contrast, thin necks in older patients with “chicken skin” lack elasticity and have poor collagen structure in addition to the diminished number of pilosebaceous units. Consequently, no amount of excessive pulling or tightening ultimately overcomes these characteristics. Indeed, attempting to compensate in these situations by excessive pulling by any surgical approach is a

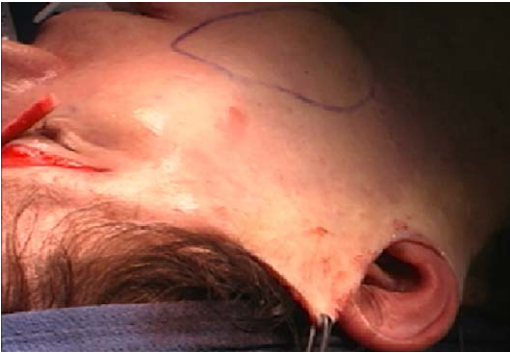

Fig. 6. Flap redraping in an oblique and vertical vector before sealant application. Note the circle depicting the area of the jawl that was liposuctioned.

futile exercise that does not benefit poor-quality skin [17].

Next, the face and neck skin is undermined widely beyond the sternocleidomastoid muscle and then across the cheek and along the jawl, freeing any retaining ligaments. The superficial musculoaponeurotic system (SMAS) in the face is addressed with a SMAS resection, SMAS plication, or anterior imbrication. The skin flaps on one side are redraped obliquely and vertically, so that the mandible no longer represents a border to the advancement of the neck skin (Fig. 6). This is done while adjusting the flap position to minimize bunching at the proximal (anterior end of sideburn) and distal (posterior lobule) incisions. The addition of the Tisseel glue provides a

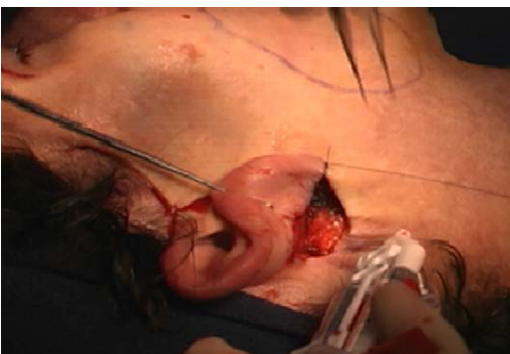

Fig. 7. Intraoperative fibrin sealant application with dual-injection device before closing. Key sutures at the helical rim and tragus. The preauricular suture begins at the lobule and is then used in a running fashion up to the helical rim. Note the redundant postauricular distal skin that redrapes and flattens. This is aided by the fibrin sealant and “walking out” the excess tissue while closing with staples.

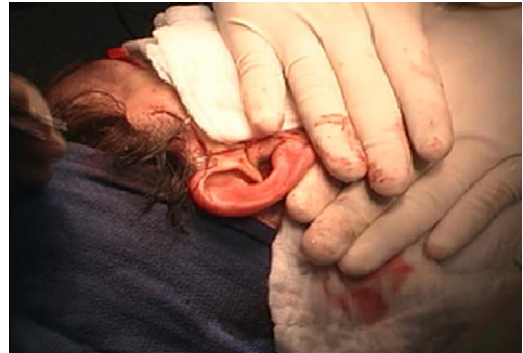

Fig. 8. Fibrin sealant is applied within 1 minute and manual pressure for 3 minutes after application. During this time, wounds are closed.

significant draping advantage in the neck and postauricular region.

After the SMAS is tightened and the skin flaps rotated, positioned, trimmed, and tacked at the apex with an absorbable suture and at the tragus with a 5-0 nylon suture, the tissue glue is sprayed in an even, thin layer (<1 mL per side) on the undersurface of the flap and on the raw dissected surfaces through the sideburn, preauricular, and postlobule incisions (Fig. 7). The preauricular incision is then closed with a 5-0 nylon suture. The Tisseel glue is sprayed in 60 seconds or less, and then external gentle pressure must be applied to the flaps with moist gauze for 3 minutes while avoiding shearing. The postauricular sulcus incision is closed with staples carefully walking out the excess skin to avoid pleating. The transverse sideburn incision is closed from lateral to medial, similarly adjusting the bulge at the lateral end that can occur. At the completion of one side, the patient is turned and surgery continues on the opposite side. Finally, final hemostasis is obtained and sealant is sprayed at the submental incision, and while pressure is applied, the wound is closed with a nylon suture. Three layers of gauze (Fig. 8) are applied and a surginet dressing.

Results

This series of 1100 patients includes men and women with age range from 34 to 82 years and includes those having primary, secondary, or more face-lifts. The senior authors (AM and SSR) performed a combined 1100 consecutive cases of short-scar face-lift, 400 prior to the use of tissue sealant, and then another 700 with tissue sealant and no

drains. Submentalplasty was performed on 824 patients (75%) who underwent the short-scar face-lift versus 10.6% of face-lift procedures performed with the traditional technique. Concomitant aesthetic procedures were performed on 750 (68%) patients. Beginning in August 2004, the senior authors have periodically inserted drains as indicated (<5%). None of their patients had hematomas or seroma formation requiring a return to the operating room.

Figs. 9–13 illustrate the use of Tisseel sealant in short-scar face-lift.

Potential problems and complications

The short scar face-lift may cause temporary bunching in the temporal and postauricular regions that often resolves. The short scar incision does not provide access to the temporal region. In patients with severely damaged neck skin, it does not allow excessive pulling or tightening, which the authors do not believe any technique did because of the damaged collagen and elastin. Rather, a process that theoretically improves the damaged

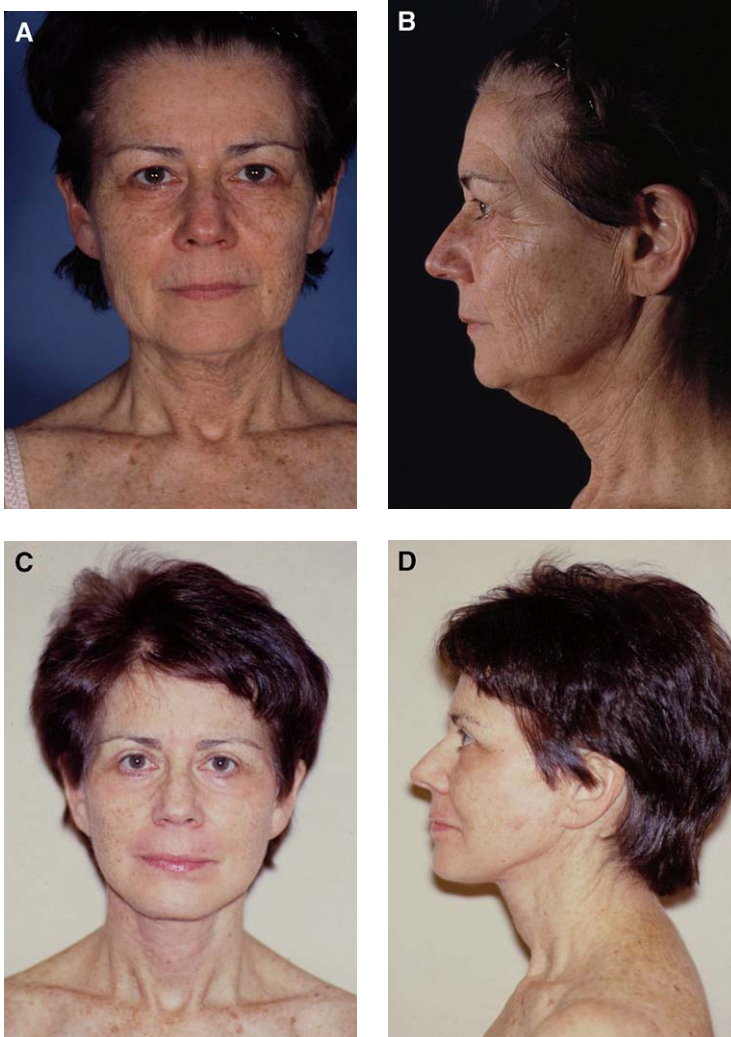

Fig. 9. (*A* and *B*) This 60-year-old woman underwent short scar face-lift, submentalplasty, upper and lower blepharoplasty, and periocular and perioral erbium laser skin resurfacing. (*C* and *D*) Postoperative views shown at 1 month. Note the dramatic improvement in neck contour with the short scar face-lift.

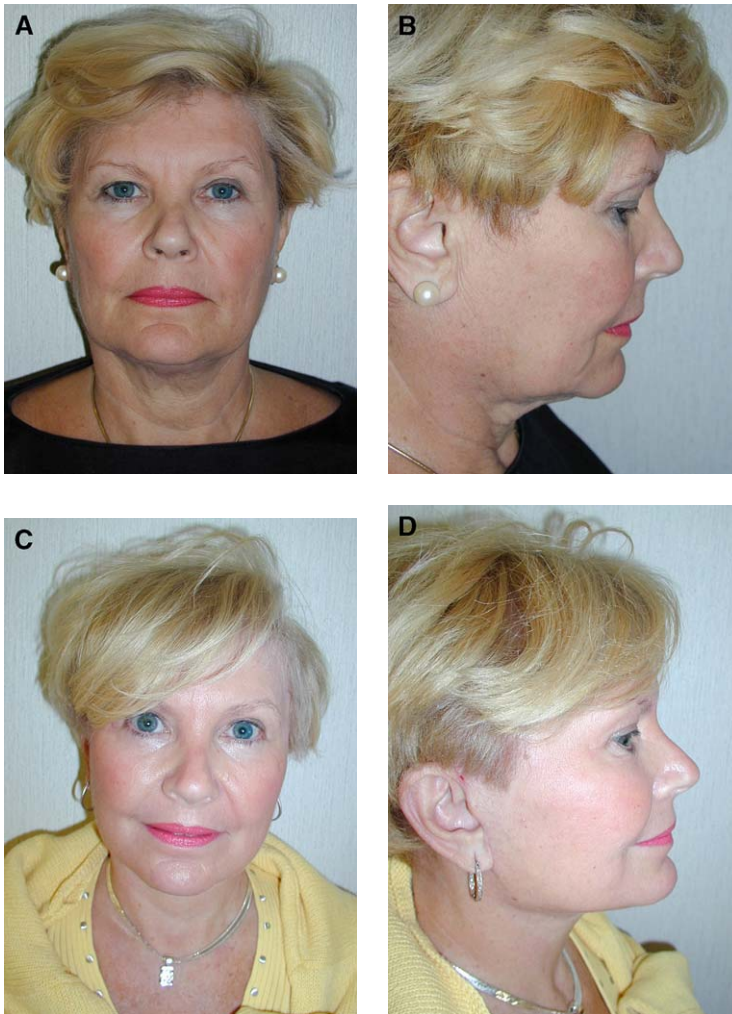

Fig. 10. (A and B) This 68-year-old woman had a short scar face-lift, submentalplasty, anterior brow-lift, upper and lower transconjunctival blepharoplasty, and perioral-periocular erbium laser skin resurfacing. (C and D) Postoperative views shown at 3 months.

skin, such as topical chemicals or nonablative lasers, radiofrequency, or intense pulse light therapy, is more appropriate.

Hematomas are the most common complication of face-lift surgery and occur in from 4% to 15% of patients [18]. In the authors' series of 1100 patients, none of the patients treated with tissue glue experienced hematoma or seroma formation requiring reoperation. Hematoma formation can lead to tissue ischemia, prolonged facial edema, hyperpigmentation, reoperation, and patient dissatisfaction.

Traditionally, the use of vacuum drains has been recommended to diminish fluid collections and reduce the incidence of hematoma formation postoperatively [18]. Drains, however, are associated with morbidity, which may include infection, tracts at site of drain removal, painful extraction, the possibility of injury to a vessel on drain removal, and the increased nursing care required for drains. Indeed, drains do not prevent hematomas. In the past, the use of drains was often routinely advised; however, this concept is now changing. Based on the

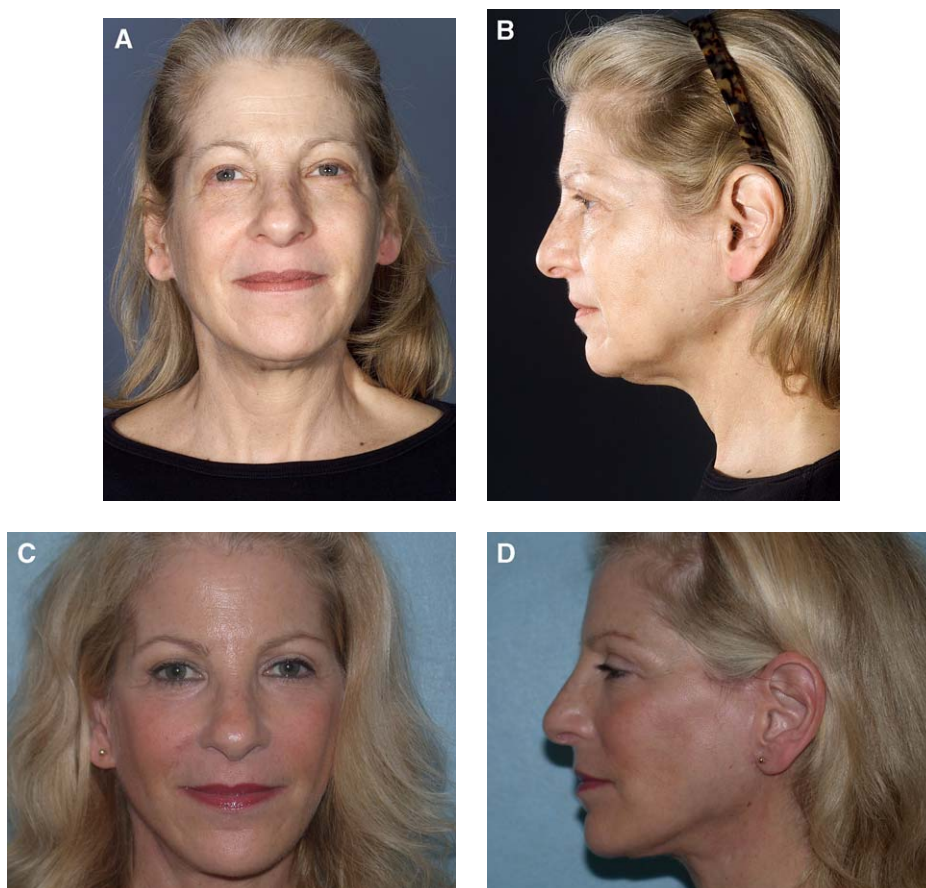

Fig. 11. (A and B) This 64-year-old woman underwent a short scar face-lift, submentalplasty, and upper and lower blepharoplasty (transconjunctival). (C and D) Postoperative views shown at 2 months.

authors' experience, the adjunctive use of fibrin sealant seems to significantly reduce the need for routine drainage in face-lift surgery.

Other studies corroborate these findings. One randomized, double-blind trial of 20 patients compared the drain output after unilateral application of fibrin sealant with the contralateral application of placebo during bilateral face-lift. Although no patient incurred the complication of hematoma or seroma, the average drainage on the treated side was 10 mL, significantly less than the control side, which drained an average of 30 mL [12]. Other retrospective studies of patients who underwent rhytidectomy, half with and half without the adjunctive use of fibrin glue, revealed significantly less postoperative ecchymosis and hematoma formation

despite the omission of drains and compressive dressings and more rapid recovery in the fibrin glue treatment arms [5,19].

In this series complications included

- Two preauricular skin ischemias (within the first 40 patients)
- Two temporary cervical nerve branch injuries (resolved within 6 months)
- Five scar revisions (three sideburns, two postlobule)
- One deep venous thrombosis or pulmonary embolism (in a patient undergoing multiple face and body procedures)
- Five patients with firm, indurated, anterior platysmarrhaphy fullness necessitating treatment

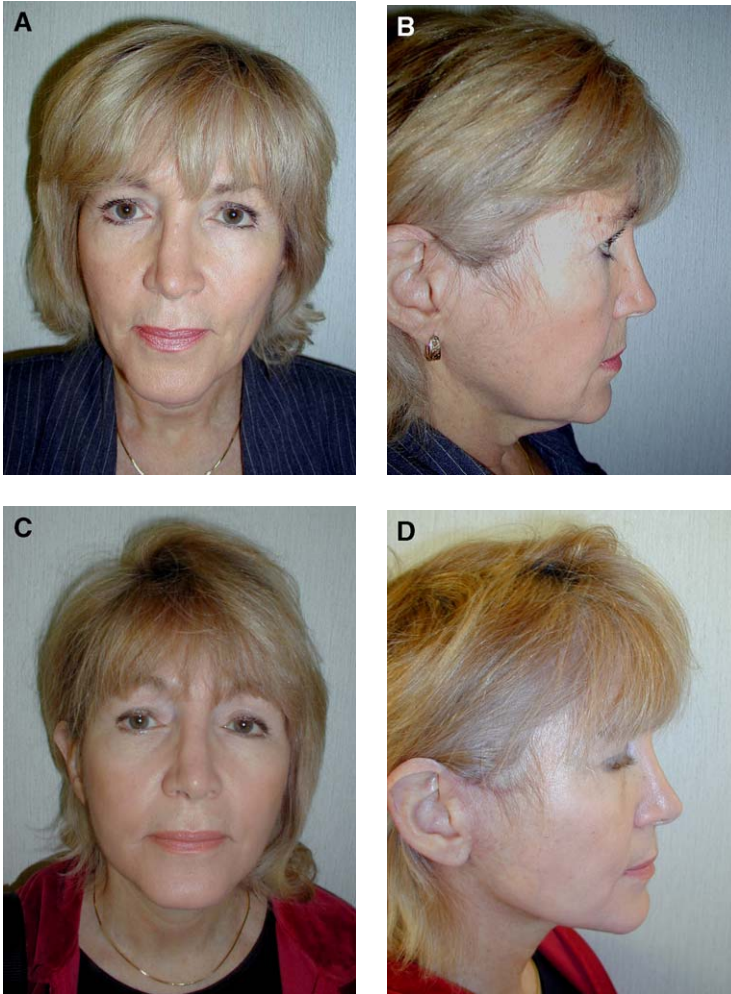

Fig. 12. (A and B) This 62-year-old woman underwent a short scar face-lift and submentalplasty. (C and D) Postoperative views shown at 6 months.

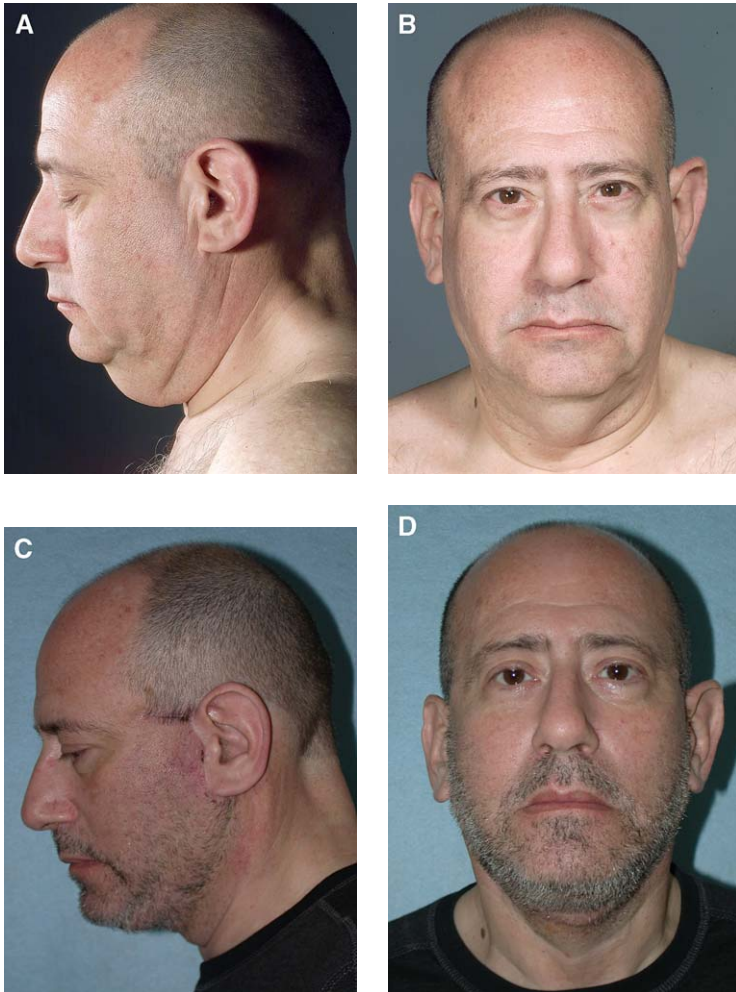

Fig. 13. (*A* and *B*) This 55-year-old man underwent a short scar face-lift and submentalplasty. (*C* and *D*) Postoperative views shown at 2 weeks.

Summary

Neither tissue sealants nor short-scar face-lift incisions are new concepts in plastic surgery; however, their routine application together in a large series of patients may be. The short scar face-lift allows all face-lift patients to avoid any hair-bearing incisions; consequently, alopecia and hairline abnormalities are eliminated, as are thickened mastoid scars and certain other flap problems. This has resulted in a high degree of patient acceptance. The shift away from a larger incision is an example of how reconsidering time-honored dogma can change long-standing medical practice. The use of Tisseel fibrin glue has enhanced the efficacy of the procedure by reducing fluid collections, shortening the recovery process, eliminating the use of drains, and facilitating flap repositioning. This series demonstrates the authors' results with the short scar face-lift in a large series of 1100 consecutive patients. Fibrin sealant aerosolized by the Tissomat and spray application device was done to achieve cost-effective, superior distribution of a critically thin sealant layer in the last 700 patients. In patients receiving the Tisseel sealant, vacuum drains were not placed postoperatively. Although hematomas remain the most common complication after face-lift surgery, none of the 700 patients treated with tissue glue in this series experienced hematoma or seroma formation that required a return to the operating room.

References

- [1] Grey EG. Fibrin as a hemostatic in cranial surgery. *Surg Gynecol Obstet* 1915;21:452.
- [2] Dresdale A, Bowman Jr FO, Malm JR, et al. Hemostatic effectiveness of fibrin glue derived from single-donor fresh frozen plasma. *Ann Thorac Surg* 1985;40:385–7.
- [3] Baxter Health Care Corporation. Tisseel vapor heated fibrin sealant. Data on File, Pamphlet 006031, 2002.
- [4] Bronstedt S, Olson S, Rank F. Wound healing and formation of granulation tissue in normal and defibrinogenated rabbits. *Eur Surg Res* 1978;10(Suppl 10):104.
- [5] Marchac D, Sandor G. Face lifts and sprayed fibrin glue: an outcome analysis of 200 patients. *Br J Plast Surg* 1994;47:306–9.
- [6] Mandel MA. Closure of blepharoplasty incisions with autologous fibrin glue. *Arch Ophthalmol* 1990;108:842–4.
- [7] Marchac D, Ascherman J, Arnaud A. Fibrin glue fixation in forehead endoscopy: evaluation of our experience with 206 cases. *Plast Reconstr Surg* 1997;100:704–12.
- [8] Dörner F. Validation of virus removal and inactivation in the course of the manufacture of sealer protein concentrate (human) vapor heated, deficient in factor VIII, using HIV-1, HAV, and model viruses: a pre-clinical study. Internal study No. PR099403. August 22, 1996.
- [9] Mannucci PM, Schimpf K, Abe T, et al. Low risk of viral infection after administration of vapor-heated factor VIII concentrate. *Transfusion* 1992;32:134–8.
- [10] Matarasso A, Rizk SS. Use of fibrin sealant in short scar facelift. In: Saltz R, Toriumi DM, editors. *Tissue glues in cosmetic surgery*. St. Louis (MO): Quality Medical Publishing; 2004. p. 134–47.
- [11] Nowotny R, Chalupka A, Nowotny C, et al. Mechanical properties of fibrinogen adhesive material. In: Winter GD, Gibbons DF, Plnck Jr H, editors. *Biomaterials*. New York: John Wiley & Sons; 1982.
- [12] Redl H, Schlag G. Properties of different tissue sealants with special emphasis on fibrinogen-based preparations. In: Schlag G, Redl H, editors. *Fibrin sealant in operative medicine, general surgery, and abdominal surgery*, vol. 6. Berlin: Springer-Verlag; 1986.
- [13] Oliver DW, Hamilton SA, Figle AA, et al. A prospective, randomized, double-blind trial of the use of fibrin sealant for face lifts. *Plast Reconstr Surg* 2001;108:2101–5.
- [14] Kjaergard HK, Trumbull HR. Vivostat system autologous fibrin sealant: preliminary study in elective coronary bypass grafting. *Ann Thorac Surg* 1998;66:482–6.
- [15] Man D, Plosker H, Winland-Brown JE. The use of autologous platelet-rich plasma (platelet gel) and autologous platelet-poor plasma (fibrin glue) in cosmetic surgery. *Plast Reconstr Surg* 2001;107:229–37.
- [16] Matarasso A, Wallach SG, Frances D, et al. Age-based comparisons of patients undergoing secondary rhytidectomy. *Aesthetic Surgery Journal* 2002;22(6):526–30.
- [17] Straith RE, Botta SA. Male face lift in continuity with lower blepharoplasty. *Aesthetic Plast Surg* 1988;12:9–21.
- [18] Baker T, Gordon H. Complications of rhytidectomy. *Plast Reconstr Surg* 1967;40:31–9.
- [19] Perkins SW, Williams JD, Macdonald K, et al. Prevention of seromas and hematomas after facelift surgery with the use of postoperative vacuum drains. *Arch Otolaryngol Head Neck Surg* 1997;123:743–5.